

Systematic Review

Current Concepts in the Treatment of Acromioclavicular Joint Dislocations

Knut Beitzel, M.A., M.D., Mark P. Cote, P.T., D.P.T., M.C.T.R., John Apostolakos, B.S., Olga Solovyova, B.S., Christopher H. Judson, M.D., Connor G. Ziegler, M.D., Cory M. Edgar, M.D., Ph.D., Andreas B. Imhoff, M.D., Robert A. Arciero, M.D., and Augustus D. Mazzocca, M.S., M.D.

Purpose: To conduct a systematic review of the literature in relation to 3 considerations in determining treatment options for patients with acromioclavicular (AC) joint dislocations: (1) operative versus nonoperative management, (2) early versus delayed surgical intervention, and (3) anatomic versus nonanatomic techniques. **Methods:** The PubMed database was searched in October 2011 using the single term *acromioclavicular* and the following search limits: *any date, humans, English, and all adult (19+)*. Studies were included if they compared operative with nonoperative treatment, early with delayed surgical intervention, or anatomic with nonanatomic surgical techniques. Exclusion criteria consisted of the following: Level V evidence, laboratory studies, radiographic studies, biomechanical studies, fractures or revisions, meta-analyses, and studies reporting preliminary results. **Results:** This query resulted in 821 citations. Of these, 617 were excluded based on the title of the study. The abstracts and articles were reviewed, which resulted in the final group of 20 studies that consisted of 14 comparing operative with nonoperative treatment, 4 comparing early with delayed surgical intervention, and 2 comparing anatomic with nonanatomic surgical techniques. The lack of higher level evidence prompted review of previously excluded studies in an effort to explore patterns of publication related to operative treatment of the AC joint. This review identified 120 studies describing 162 techniques for operative reconstruction of the AC joint. **Conclusions:** There is a lack of evidence to support treatment options for patients with AC joint dislocations. Although there is a general consensus for nonoperative treatment of Rockwood type I and II lesions, initial nonsurgical treatment of type III lesions, and operative intervention for Rockwood type IV to VI lesions, further research is needed to determine if differences exist regarding early versus delayed surgical intervention and anatomic versus nonanatomic surgical techniques in the treatment of patients with AC joint dislocations. **Level of Evidence:** Level III, systematic review of Level II and Level III studies and one case series.

From Department of Orthopaedic Surgery (K.B., M.P.C., J.A., O.S., C.D., C.Z., C.E., R.A.A., A.D.M.), University of Connecticut Health Center, Farmington, Connecticut, U.S.A.; Department of Trauma and Orthopedic Surgery (K.B.), Trauma Center Murnau, Murnau, Germany; and Department of Orthopaedic Sports Medicine (A.B.I.), Technical University Munich, Munich, Germany.

The authors report the following potential conflict of interest of source or funding in relation to this article: R.A. received a grant from Arthrex; A.M. received a grant from and A.M. and A.B.I. are consultants for Arthrex; and A.M. has grants pending from Arthrex and Donohugh Grant. The University of Connecticut Health Center/New England Musculoskeletal Institute has received direct funding or material support from Arthrex, Inc. The company had no influence on study design, data collection, or interpretation of the results or the final manuscript.

Received September 24, 2012; accepted November 27, 2012.

Address correspondence to Augustus D. Mazzocca, M.D., M.S., University of Connecticut Health Center, Department of Orthopaedic Surgery, Farmington, CT 06034, U.S.A. E-mail: mazzocca@uchc.edu

© 2013 by the Arthroscopy Association of North America

0749-8063/12633/\$36.00

<http://dx.doi.org/10.1016/j.arthro.2012.11.023>

Note: To access the supplementary Appendix accompanying this report, visit the February issue of *Arthroscopy* at www.arthroscopyjournal.org.

Treatment of the acromioclavicular (AC) joint remains subject to debate because of the lack of consensus regarding the optimal management method for injuries to the joint. By its appearance, the AC joint seems to have a simple structure; however a growing body of laboratory-based research has found the biomechanics of the motion that occurs between the clavicle and acromion to be complex and not yet fully understood. Literature regarding treatment options for patients with AC injury is replete with descriptions of surgical techniques. Additionally, data regarding the epidemiology of injury may not always be reliable. For example, the incidence of injury to the joint is often reported to be either 9% or 12% of all injuries to the shoulder; however review of citations reveals the source of these percentages to be a book by Edwin Cave in 1958¹ that included a report by Rowe and Marble on an analysis of 1,603 shoulder girdle injuries, 52 (3.2%) of which were injuries to the AC

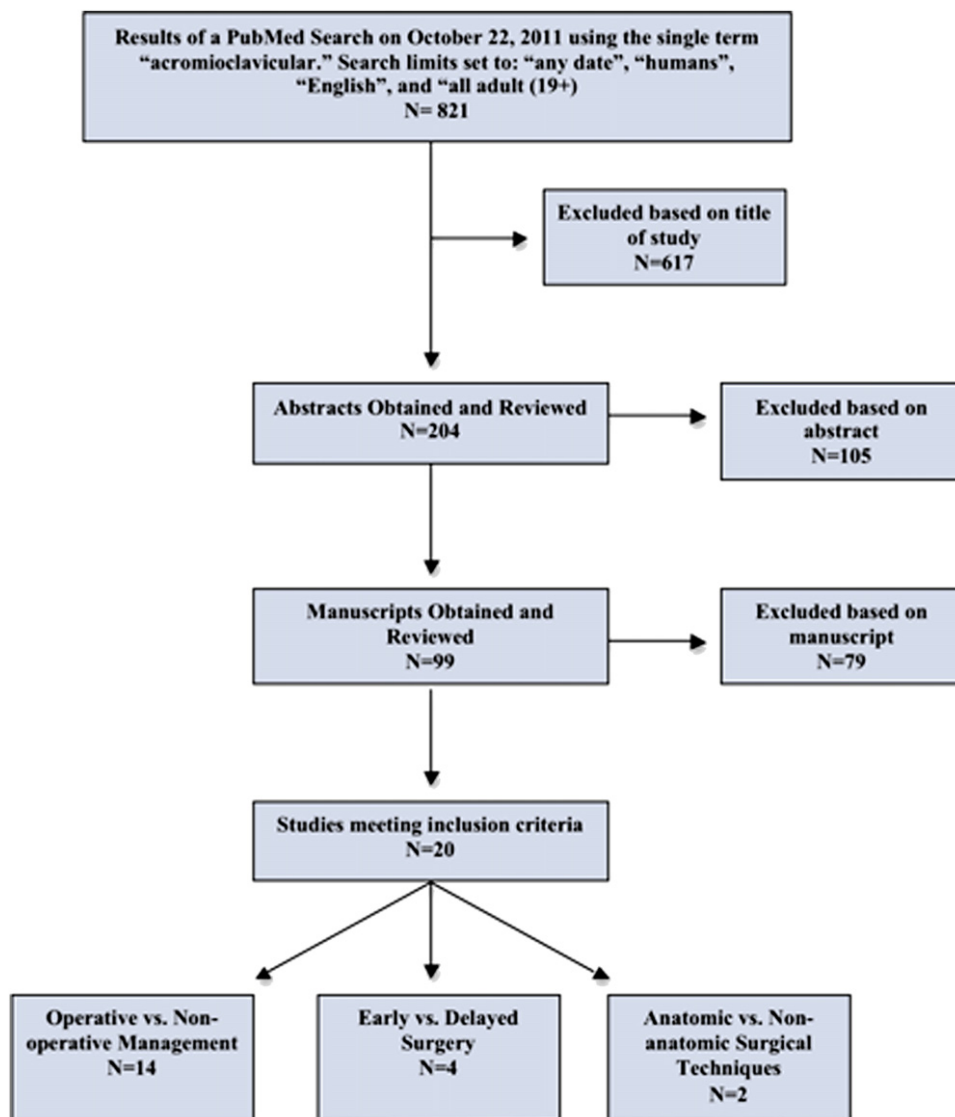


Fig 1. Flow diagram for enrollment. Exclusion criteria consisted of the following: Level V evidence, laboratory studies, radiographic studies, biomechanical studies, fractures or revisions, meta-analyses, and studies reporting preliminary analysis.

joint. Despite the miscalculated and inconsistent references to this book (including the past publications of the senior author), recent reports have indicated AC joint injuries to be among the most common orthopaedic injuries to the shoulder in a young athletic population.^{2,3}

Rockwood and Green⁴ described 2 fundamental schools of thought in the consideration of treatment options for patients with AC joint separations: (1) conservative or nonoperative treatment and (2) surgical repair.⁵ Although simple in concept, the abundant number of surgical techniques described in the current literature makes it difficult to discern which techniques or approaches work best for a given AC separation. Further, considerations regarding the timing of surgical intervention and the type of reconstruction need to be explored to elucidate a management scheme that maximizes the potential for a favorable treatment outcome for patients with AC joint separation.

The purpose of this study was to conduct a systematic review of the literature regarding 3 considerations in determining treatment options for patients with AC joint dislocations: (1) operative versus nonoperative management, (2) early versus delayed surgical intervention, and (3) anatomic versus nonanatomic techniques.

Methods

A single investigator conducted a search of the PubMed database in October 2011 using the single term *acromioclavicular* and the following search limits: *any date*, *humans*, *English*, and *all adult (19+)*. Studies were included if they compared operative with nonoperative treatment, early with delayed surgical intervention, or anatomic with nonanatomic surgical techniques. Exclusion criteria consisted of the following: Level V evidence, laboratory studies, radiographic studies, biomechanical studies, fractures or revisions, meta-analyses, and studies reporting preliminary results.

Studies meeting all criteria were reviewed and the following data were abstracted: study design, Level of evidence, treatments compared, number of patients, mean age, length of follow-up, and the measures used to determine treatment outcome. Level of evidence was assigned according to the *Arthroscopy* journal's Levels of Evidence for Primary Research. The abstracted data for each study were categorized to one of 3 groups: (1) operative versus nonoperative management, (2) early versus delayed surgical intervention, and (3) anatomic versus nonanatomic techniques. Additionally, the Detsky scale and Cochrane Risk of Bias tool were used to appraise the quality of studies that used a randomized clinical trial design. Two independent reviewers appraised each study with a randomized clinical trial design using both tools. Any conflicting scores on either the Detsky scale or the Cochrane Risk of Bias tool were resolved by discussing the item in question with a third reviewer.

During the screening of citations for eligibility, it became apparent that there was a lack of high-level evidence, and the decision was made to display all operative techniques identified through the search. To more effectively evaluate these data, the reported techniques were separated into one of the 3 following categories: (1) anatomic: reproduction of both the conoid and trapezoid ligaments by means of graft or nonabsorbable suture; (2) nonanatomic: reproduction of a single coracoclavicular (CC) ligament or a technique without the use of internal fixation hardware; or (3) nonanatomic open reduction internal fixation (ORIF)—fixation of the joint using hardware including plates, screws, wires, or pins.

Results

The search resulted in 821 citations. Of these, 617 were excluded based on the title of the study. The abstracts of the remaining 204 citations were then reviewed, which resulted in an additional 105 exclusions. The articles of each of the remaining 99 citations were then obtained and reviewed, which resulted in 79

exclusions. The final group of 20 studies consisted of 14 comparing operative with nonoperative treatment, 4 comparing early with delayed surgical intervention, and 2 comparing anatomic with nonanatomic surgical techniques. Of these studies, 2 used a randomized clinical trial design, 2 prospectively compared treatment groups, and 16 retrospectively compared treatment groups (Fig 1). Of the 2 studies that used a randomized clinical trial design, Larsen et al.⁶ scored 17 (81%) and Bannister et al.⁷ scored 11 (52%) on the Detsky scale. The Cochrane Risk of Bias assessments for the 2 studies are shown in Fig 2.

Operative Versus Nonoperative Management

Of the 20 studies included in this review, 14 compared operative with nonoperative treatment. Three of these studies were prospective Level II studies, whereas the remaining 11 were retrospective (Level III) studies (Table 1). A cumulative total of 706 patients were included in these studies with a mean follow-up of 67.1 months and 57.8 months for the operative and nonoperative groups, respectively. A favorable clinical outcome defined as good or better was reported in 88% of the operatively managed patients compared with 85.5% of the nonoperatively managed patients. Anatomic reduction of the joint was achieved in 59% of the operatively treated patients and in only 14.7% of the nonoperatively treated patients. Evaluating factors such as return to work and return to sport revealed a quicker recovery for the nonoperative patients, who needed roughly half the time to return to their previous level of activity.

Early Versus Delayed Surgery

Four of the 20 studies compared early to delayed surgical treatment (Table 2). All 4 studies in this category were retrospective comparative studies (Level III). A cumulative total of 113 patients were categorized as early repairs and 76 patients were categorized as delayed repairs based on the study's description

Larsen E. et al 1986	+	+	+	-	-	-
Bannister G. et al 1989	+	?	?	?	-	+
	Random Sequence Generation	Allocation Concealment	Blinding of Participants Personnel, Outcome Assessors	Incomplete Outcome Data	Selective Outcome Reporting	Other Potential Threats
	+ : Yes (low risk of bias) - : No (high risk of bias) ? : Unclear risk of bias					

Fig 2. Risk of bias assessment according to the Cochrane Collaboration's bias tool.

Table 1. Clinical Studies Evaluating Operative versus Nonoperative Treatment of AC Joint Injuries

Study	Design, Level of Evidence	Patients		Mean Age (yr)		Mean Follow-up (mo)	
		Operative	Nonoperative	Operative	Nonoperative	Operative	Nonoperative
Rosenorn and Pedersen, 1974 ⁴¹	Retrospective comparative, III	11	13	37	41.5	12.25	84
Galpin et al., 1984 ⁴²	Retrospective comparative, III	16	21	28.9	36.7	35	33.7
Jacobs et al., 1966 ⁴³	Retrospective comparative, III	51	43	34.8	47.9	124.2	100.7
Calvo et al., 2006 ⁴⁴	Retrospective comparative, III	32	11	39.6	34.5	122.8	40.5
MacDonald et al., 1988 ⁴⁵	Retrospective comparative, III	10	10	25	31.7	5.7	6.3
Larsen et al., 1986 ⁶	Lesser RCT, II	41	43	36	36	13	13
Taft et al., 1987 ⁴⁶	Retrospective comparative, III	52	75			129.6	124
Gstettner et al., 2008 ⁴⁷	Retrospective comparative, III	24	17	37.2	36.2	32.1	36.8
Walsh et al., 1985 ⁴⁸	Retrospective comparative, III	9	8	30.7	29.7	25.3	29.9
Bakalim and Wilppula, 1975 ⁴⁹	Retrospective comparative, III	19	22			51.6	
Bannister et al., 1989 ⁷	Lesser RCT, II	27	33	32.5		48	48
Larsen and Hede, 1987 ⁵⁰	Prospective comparative, II	23	55	35 (median)		12	
Press et al., 1997 ⁵¹	Retrospective comparative, III	16	10	30.7	49.6	32.3	33.4
Cardone et al., 2002 ⁵²	Retrospective comparative, III	6	8	26.7	29	44.8	29.5
		33.7	369	34.9	38.1	671	57.8

RCT, randomized controlled trial

*Favorable outcomes as determined by authors in literature. An outcome defined as "good" or better was considered a favorable outcome.

†Incomplete data due to loss of follow-up of enrolled study patients.

‡Patient rated outcome on 4-point Likert scale (4 being normal).

of classification. A favorable outcome, as specifically defined by the authors in each study, was achieved in 103 (91%) early treatments compared with 55 (72%) delayed treatments.

Weinstein et al.⁸ described the time point distinguishing acute versus delayed surgery as 3 weeks from the date of injury. All cases were repaired with nonabsorbable AC sutures. A Weaver-Dunn procedure was performed in all the delayed reconstructions ($n = 17$) and in 15 of the 27 early reconstructions. Satisfactory results were achieved in 96% of the early and 76% of the delayed treatments at a mean follow-up of 4 years (range, 2 to 9 years). A statistically significant difference favoring early treatment was found in cases in which the delayed reconstruction was performed more than 3 months after injury.

Rolf et al.⁹ compared a group of patients undergoing reconstructions immediately after trauma (early group) to a group of patients who had reconstruction after failure of conservative treatment. In the early repair group, 29 patients were treated with a modified Phe-mister technique, which was performed according to Mayr. This technique included augmentation of the CC ligaments with polydioxanone suture, and an additional No. 1-0 polydioxanone cord was passed around the base of the coracoid and formed into a figure-of-8-shaped sling through a drill in the lateral clavicle. The AC joint was finally transfixed with a K-wire across the joint space. In the delayed-treatment group, 20 patients were treated with a modified Weaver-Dunn procedure and additional AC joint resection. After a follow-up of 53 months (range, 20 to 92 months), the authors reported a statistically significant difference ($P = .019$) in clinical results favoring the early treatment of injuries.⁹

Mignani et al.¹⁰ compared patients treated less than 30 days after injury (early group) to patients treated more than 30 days after injury. The study consisted of 40 patients (25 early/15 delayed) with a mean follow-up of 84 months (range, 12 to 132 months). The patients of the early group received surgical treatment at a mean of 5 days, whereas the delayed group received treatment at a mean of 150 days. The authors described 3 surgical techniques for repair, including CC wiring with multiple nonresorbable cables with temporary AC joint fixation, metal wiring of the Dall-Miles type, and tangential resection of the clavicle according to the Mumford method modified by Gui. This study reported satisfactory outcomes in 93% of the delayed group compared with 100% of the early group.

Dumontier et al.¹¹ compared patients treated in the first few days after injury (early group) to those seen more than 3 weeks after injury (delayed group). The study consisted of 56 patients (32 early/24 delayed) treated by transfer of the coracoacromial ligament to reproduce the CC ligament. In the early repair group, 30 patients (94%) returned to work and 23 (82%) athletes returned to their respective sport. In the delayed repair group, 22 patients (97%) returned to work and 10 (77%) patients returned to their respective sport. This study reported favorable outcomes in 81% and 79% of early and delayed treatments, respectively.

Anatomic Versus Nonanatomic Surgical Techniques

Of the 20 studies included in the review, 2 studies matched our definitions of anatomic and nonanatomic surgical repairs (Table 3). One study was prospective comparative in design (Level II) and one was retrospective comparative in design (Level III). Cumulative

Table 1. Continued

Return to Work		Return to Sport		Anatomic Reduction		Favorable Outcomes*	
Operative	Nonoperative	Operative	Nonoperative	Operative	Nonoperative	Operative	Nonoperative
9 wk	6 wk			3 (27%)	3 (27%)†	5 (45%)	7 (54%)
6.8 wk	2.6 wk	8.8 wk	6.8 wk	13 (81%)	0 (0%)	12 (75%)	15 (71%)
				4 (8%)	29 (57%)	44 (86%)	38 (88%)
				16 (50%)	0 (0%)	31 (97%)	9 (82%)
				3.5/4.0 mean‡	2.6/4.0 mean‡	2.5/4.0 mean‡	2.2/4.0 mean‡
8 wk	6 wk			37 (95%)†	0 (0%)†	38 (97%)†	39 (98%)†
				37 (71%)	3 (4%)	49 (94%)	68 (91%)
23 (96%)	14 (82%)	16 (67%)	11 (65%)	11.6 ± 4.6 mm	14.1 ± 4.9 mm	21 (88%)	10 (59%)
				3.0/4.0‡	2.8/4.0‡	2.8/4.0 mean‡	3.1/4.0 mean‡
12 wk	5 wk			12 (63%)	3 (14%)	14 (74%)	13 (59%)
11 wk	4 wk	16 wk	7 wk	12 mm	16 mm	23 (85%)	33 (100%)
6 wk	5.5 wk			18 (78%)	4 (7%)	23 (100%)	53 (96%)
10.4 wk	3.2 wk	25.6 wk	14 wk	10 (77%)†	0 (0%)†	17/20 mean score	15.4/20 mean score
		18.8 wk	26.2 wk			4 (66%)	4 (50%)
8.9 wk	4.9 wk	16.8 wk	10.0 wk	150 (59%)	42 (14.7%)	264 (88%)	289 (85.5%)

totals included 42 patients in both the anatomic and nonanatomic repair groups. The 2 studies used different evaluation measures; however both studies demonstrated favorable results for the anatomic procedures.

Tauber et al.¹² conducted a prospective comparative study evaluating 24 patients at a mean follow-up of 37 months. The anatomic procedure was performed in 12 patients and used a semitendinosus graft for reconstruction of the conoid and trapezoid ligaments through two 4.0-mm-diameter holes drilled in a superior-inferior direction. The results of this technique were compared with the 12 patients who received the nonanatomic Weaver-Dunn procedure. This study reported more favorable clinical outcomes for the anatomic reconstruction based on mean postoperative American Shoulder and Elbow Surgeons (ASES) scores (96 ± 5 v 86 ± 8) and mean postoperative constant scores (93 ± 7 v 81 ± 8).

Fraschini et al.¹³ conducted a retrospective comparative study to evaluate the treatment of 60 patients at a mean follow-up of 15 months. The anatomic procedure performed in this study used an artificial ligament (Ligament Augmentation and Reconstruction System [LARS]) that was passed through 2 transosseous tunnels drilled into the clavicle. The ligament was passed around the coracoid and secured in the clavicle with 2 conic interference screws, reproducing the conoid and trapezoid ligaments. This technique was compared with a group receiving a nonanatomic treatment with a polyester vascular prosthesis passed around the coracoid and secured over the clavicle with a knot. The study concluded that satisfactory outcomes were achieved in 28 patients (93%) who received the anatomic technique compared with 16 patients (53%) who received the nonanatomic procedure.

Overview of Described Surgical Techniques for AC Joint Reconstruction

Review of the 821 citations revealed 120 studies describing 151 techniques for operative reconstruction of the AC joint. Of the 120 studies: 85 (70%) met Level IV, 28 (23%) met Level III, and 7 (6%) met Level II criteria. Of the 151 techniques, 13 were anatomic, 48 were nonanatomic, and 90 were nonanatomic ORIF. A comparative summary of these studies is somewhat prohibitive because varying and often subjective criteria were used to determine satisfactory treatment outcome. An extended overview of these studies can be seen in Appendix 1 (available online at www.arthroscopyjournal.org).

Discussion

The goal of this systematic review was to examine the evidence as it relates to the treatment of patients with AC joint dislocations. We used basic search criteria in an effort to capture all available research pertaining to AC joint dislocation. Although this search produced 821 citations, only 20 studies meet our inclusion criteria, the majority of which were Level III evidence. The paucity of quality research makes it difficult to draw overall conclusions regarding treatment options. In this context, current concepts based on the available literature for the treatment of AC joint dislocations are presented.

Operative Versus Nonoperative Management

The uncertainty surrounding treatment of AC joint injury can be traced back to the earliest medical writings of Hippocrates and Galen.⁴ The first "modern" surgical procedures were performed in the 1860s. In the 1930s and 1940s, several conservative treatment

Table 2. Clinical Studies Evaluating Early versus Delayed Surgical Treatment of AC Joint Injuries

Study	Design, Level of Evidence	Patients		Mean Age (yr)		Mean Follow-up (mo)	
		Early Treatment	Delayed Treatment	Early	Delayed	Early	Delayed
Rolf et al., 2008 ⁹	Retrospective comparative, III	29	20	37	46	54	52
Weinstein et al., 1995 ⁸	Retrospective comparative, III	27	17	31	34	48	
Mignani et al., 2002 ¹⁰	Retrospective comparative, III	25	15	30		84	
Dumontier et al., 1995 ¹¹	Retrospective comparative, III	32	24	37	39	46	51
	TOTAL	113	76	34	38	57	57

*Favorable outcomes as determined by authors in literature. An outcome defined as "good" or better was considered a favorable outcome.

†Percentage based on number of patients working and/or actively playing sports at time of surgery.

options were described and the trend for treatment favored a nonoperative approach. In 1941, Bosworth¹⁴ introduced his technique of blind insertion of a bone screw from the clavicle down into the coracoid. At the same time Mumford¹⁵ described his resection of the lateral 2 cm of the clavicle. Since the 1970s, surgeons have generally agreed on the premise of treating high-grade lesions surgically and mild lesions of the AC joint conservatively.¹⁶

Based on our review, there is a general consensus for nonoperative treatment of Rockwood type I and type II lesions.^{12,17,18} Historically, literature varied regarding the most favorable method of conservative management of AC joint dislocations. Rockwood distinctly divided the various forms of conservative treatment into 2 classifications: (1) the use of a harness or sling as an immobilization device and (2) so-called skillful neglect.⁴ There are several variations of immobilization devices such as slings and harnesses that date back to the 1930s and 1940s. These variations include slings, adhesive tape strappings, braces, harnesses, traction techniques, and plaster casts.⁴ Regardless of the form of conservative treatment, the general agreement was the need for "uninterrupted continuous pressure" on the superior surface of the distal clavicle to allow for ligament healing.⁴

Currently, the most accepted method of conservative treatment is a brief period of immobilization in a sling to support the weight of the upper extremity and to limit the stress on the joint's ligaments.^{5,17,19,20} This period of immobilization is accompanied by ice and oral analgesic medication if tolerated (typically lasting 3 to 7 days). The patient is encouraged to initiate range of motion activities within the first week of injury to reduce pain and inflammation in an effort to decrease associated morbidity. Strengthening exercises with a specific focus on scapular stabilization follow. During this time, heavy lifting and contact sports are to be avoided to allow ligament healing.^{5,16,18}

In contrast to the treatment of type I and type II lesions, there is a general uncertainty regarding the proper treatment of type III dislocations; however initial nonoperative treatment is currently favored in most cases.¹⁸ Recent studies have shown that conservatively treated type III lesions may result in altered motion of

the scapula.²¹ During management of type III lesions in an athlete, individualized treatment should take into consideration factors such as type of sport, timing of injury relative to athletic season, level of play, and throwing demands on the affected shoulder. Some of the uncertainty regarding the proper treatment of type III lesions is due to the difficulty associated with precisely defining these lesions and clearly differentiating them from a type V lesion. Current literature suggests the decision for treatment of type III injuries should be made on a case-by-case basis with an emphasis on initial nonoperative treatment.^{20,21} In our opinion, a patient with a grade III AC separation qualifies for surgical reconstruction if they present persistent symptoms and functional limitations after a course of nonoperative management focused on attaining full range of motion and scapula stabilization.²⁰ Operative treatment is generally the accepted method for complete AC joint injuries (types IV, V, and VI) because of the significant morbidity associated with persistently dislocated joints and severe soft tissue disruption.

Despite this general consensus for management of AC separations by grade of injury, the 2 Level II studies included in this review found nonoperative treatment to produce a better outcome when compared with operative treatment.^{6,7} Of note, both studies were performed in the late 1980s when surgical techniques to reconstruct the AC joint were less refined and developed than those used today.

Early Versus Delayed Surgery

On the basis of our review, there is a lack of research to support an optimal time point for surgical intervention in AC joint dislocations. The 4 studies included in this review used several different methods of reconstruction (e.g., pin *v* Weaver-Dunn procedure). These variations in treatment may have a considerable influence on the outcome—specifically if nonanatomic techniques were used and resections of the distal clavicle were performed simultaneously. Although these 4 retrospective studies (Level III evidence) suggest there may be a benefit for early repair compared with delayed procedures, the quality of the evidence substantially limits the strength and certainty of this conclusion.⁸⁻¹¹

Table 2. Continued

Return to Work		Return to Sport		Anatomic Reduction		Favorable Outcomes*	
Early	Delayed	Early	Delayed	Early	Delayed	Early	Delayed
				9 (31%)	3 (15%)	26 (90%)	9 (45%)
		19 (100%)†	7 (78%)†	23 (85%)	12 (71%)	26 (96%)	13 (76%)
30 (94%)	22 (97%)†	23 (82%)†	10 (77%)†			25 (100%)	14 (93%)
30 (94%)	22 (97%)	42 (89%)	17 (77%)	32 (57%)	15 (41%)	26 (81%)	19 (79%)
						103 (91%)	55 (72%)

Because of the lack of evidence supporting the surgical management of grade III and grade IV AC separations, we recommend initially treating all patients with 3 to 4 weeks of nonoperative management and re-evaluating clinical symptoms after this time.²⁰ In our experience, some of these conservatively treated patients have persistent pain and are unable to return to their sport or job. If operative procedures are used, surgical techniques that do not integrate tendon grafts or other biological material should be performed within the first weeks after injury. This is largely based on the idea that narrowing the clavicle to the scapula will allow sufficient healing of the freshly ruptured soft tissues. Conversely, if tendon grafts are incorporated into the repair, immediate surgical intervention may not be of such importance.

Anatomic Versus Nonanatomic Surgical Techniques

As we performed this systematic review, we found an abundance of case series and comparative studies on surgical techniques for AC joint reconstruction. We believe it is important to present this large body of research on differing techniques to show the lack of a single, conclusively effective surgical technique. In our opinion, no technique has been shown to be the overall gold standard for operative treatment of AC joint dislocations nor has a technique demonstrated successful reconstruction of the complicated structure of the AC joint stabilizers.^{5,22} Additionally, we find it important to point out the varying, and oftentimes subjective, outcome measures used by these studies. The criteria for determining successful and favorable outcomes are inconsistent among studies and is often based on definitions described by individual studies and authors. This inconsistency, in addition to the subjective evaluation tools used by these studies, makes it nearly impossible to objectively compare outcomes between studies.

Interestingly, most of the described techniques covered in this review are variations and combinations of historically described surgical techniques. This finding is in agreement with Rockwood who broke down all surgical repairs of the AC joint into 4 basic groups: (1) AC repairs, (2) CC repairs, (3) excision of the distal clavicle, and (4) dynamic muscle transfer.⁴

The fact that “new” techniques recovered in this search can be categorized as a variant or combination of one or more of the basic groups described by Rockwood provides further evidence that a single effective technique for AC joint reconstruction remains unknown.

The progression of historically described techniques for AC joint reconstruction was described by Rockwood and Green⁴ based on Cadenat’s article in 1917.²³ Samuel Cooper is credited for performing the first operation on the AC joint using a wire loop to repair the AC joint in 1861. This was followed by procedures describing the direct repair of the AC ligaments while not addressing the CC ligaments. In 1886 Baum is credited for being the first to combine repair of the AC and CC ligaments. In 1917 Delbet performed the first CC reconstruction using a suture looped around the coracoid and fixed in clavicular bone tunnels. Delbet believed that a rigid repair of these structures was prone to failure and therefore used flexible suture loops. That same year Cadenat used the coracoacromial ligament to reconstruct the CC ligament. In 1941, Bosworth¹⁴ described his technique of placing a screw between the clavicle and the coracoid. A procedure combining this technique with the resection of the lateral clavicle was then described by Weaver and Dunn in 1972.²⁴ Nearly all of today’s techniques are based on these procedures developed in the late 1800s and early 1900s (Fig 3).

Temporary pin fixation remains one of the most common direct repairs of the AC ligaments because this relatively easy technique can be performed quickly under direct visualization. Variations of this technique using the meniscus to reinforce the superior AC ligament were described by Sage and Salvatore.²⁵ Zaricznyj²⁶ modified the temporary fixation of the AC joint using pins by adding a reconstruction of the AC and CC ligaments using the tendon of the fifth toe extensor. Bundens and Cook²⁷ emphasized the importance of reefing the attachment of the trapezoid and deltoid muscles over each other on top of the clavicle. We also suggest this technique of reefing the fascia to finally reinforce the AC ligaments when performing the authors’ open anatomic procedure (anatomic coracoclavicular reconstruction [ACCR]).^{28,29}

Table 3. Clinical Studies Evaluating Anatomic versus Nonanatomic Techniques

Study	Design, Level of Evidence	Type of Fixation	Technique	Patients	Mean Age (yr)	Mean Follow-up (mo)	Evaluations (mean)		Anatomic Reduction	Favorable Outcomes*
							Before Treatment	After Treatment		
Tauber et al., 2009 ¹²	Prospective case series, IV	Anatomic	Autogenous semitendinosus tendon graft to reproduce CC ligaments	12	42	37	ASES 74 ± 4, CS 71 ± 5	ASES 96 ± 5, CS 93 ± 7	Mean CC distance 11.4 ± 3 mm with 10-kg load 11.8 ± 3 mm	
Fraschini et al., 2010 ¹³	Retrospective comparative, III	Nonanatomic	Modified Weaver-Dunn	12	31.5	15	ASES 74 ± 7, CS 70 ± 8	ASES 86 ± 8, CS 81 ± 8	Mean CC distance 12.3 ± 4 mm with 10-kg load 14.9 ± 6 mm	Satisfactory outcome in 28 patients (93%)*
		Anatomic	Two tunnels drilled into clavicle, LARS then passed around the coracoid and through tunnels, secured with 2 conic interference screws	30			UCLA 15.3 ± 1.1	UCLA 28.4 ± 2.3		
		Nonanatomic	Polyester vascular prosthesis passed around coracoid and secured over clavicle	30				UCLA 27.9 ± 2.2		Satisfactory outcome in 16 patients (53%)*

ASES, American Shoulder and Elbow Surgeons; CC, coracoclavicular; CS, Constant Score; LARS, Ligament Augmentation and Reconstruction System; UCLA, University of California, Los Angeles.
*Favorable outcomes as determined by authors in literature. An outcome defined as "good" or better was considered a favorable outcome.

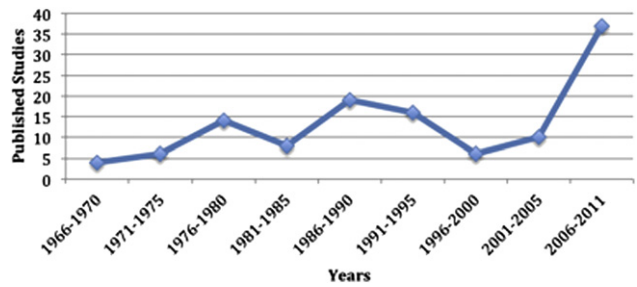


Fig 3. Outcome studies reporting on surgical techniques (April 1966 to October 2011).

Despite the abundance of studies describing operative techniques for AC joint reconstruction, very few are of high level according to current evidence rating scales. Many of the current techniques focus on reconstruction of the CC ligaments in reference to anatomic studies that have emphasized the biomechanical importance of the CC ligaments for vertical stability in reconstructions of the AC joint. Current anatomic techniques focus on reconstruction of both the conoid and trapezoid ligaments, which can be performed as open or arthroscopically assisted procedures. Additional reconstruction of the AC ligaments could be performed, which would result in a complete reconstruction of all stabilizing ligament structures.

Based on our inclusion criteria and our definitions of *anatomic* and *nonanatomic* repairs, only 2 studies were identified that clinically evaluated an anatomic reconstruction technique compared with a nonanatomic control.^{12,13} Both studies reported postoperative clinical outcomes favoring the anatomic technique. The study performed by Fraschini et al.¹³ used a synthetic ligament for their reconstruction technique, whereas Tauber et al.¹² used a biologic graft (semitendinosus tendon). The anatomic techniques used in the studies included reconstruction of both the conoid and trapezoid ligaments. Similar to the lack of literature observed for early versus delayed treatment, the quality of the evidence substantially limits the strength and certainty of the conclusion that anatomic treatment provides a greater benefit to the patient than a nonanatomic approach.

Our Preferred Techniques for Anatomic Reconstruction of the AC Joint

Based on the results of this review, our clinical experience, and the results of our biomechanical studies, we believe that the achievement of satisfactory long-term results after surgical intervention is dependent on several anatomic principles.²⁹⁻³² These principles include (1) respect for the bony anatomy of the clavicle and the acromion. In agreement with this principle, no extensive resection of the distal clavicle should be performed because this would further increase the instability of the construct. (2) Both CC

ligaments (conoid and trapezoid) should be reconstructed out of respect for their specific function and overall contribution to joint stability. (3) The reconstruction should allow the complex 3-dimensional motion pattern of the joint without jeopardizing the construct's stability.

In cases of acute high-grade type IV to V lesions, we prefer a double cortical button technique according to the description of Walz et al.³³ if surgical reconstruction can be accomplished within the first few weeks after injury. The basic idea of this technique is to place 2 cortical button pulley devices through the clavicle and coracoid into an anatomic position with respect to both the conoid and trapezoid ligaments. Performed within the first weeks after the initial injury, this technique is believed to treat the clavicle and acromion in a physiologic way to promote healing of the torn AC and CC ligaments.³⁴

As in every surgical procedure, the glenohumeral joint is first inspected carefully for any additional lesions. Studies have shown a high correlation of glenohumeral lesions in AC joint dislocations.^{35,36} A lateral portal for the arthroscope and 2 anterior working portals are used to prepare the coracoid. With the help of the aiming instrument, two 4-mm tunnels are drilled through the clavicle and the coracoid after arthroscopic debridement of the coracoid's undersurface. Anatomic positioning during reproduction of the conoid and trapezoid ligaments is essential and can be accomplished by placing the tunnels accordingly.^{37,38} Finally 2 suture pulley systems (TightRope; Arthrex, Naples, FL) are passed through the tunnels and fixed after tensioning the sutures. Biomechanical studies have demonstrated the biomechanical performance of such reconstruction methods.^{31,33}

In cases of delayed therapy or failed conservative treatment, the ACCR allows for simultaneous reconstruction of the CC ligaments (trapezoid and conoid) and the AC ligaments for optimized restoration of biomechanical function.²⁸ This technique restores function of both the CC and AC ligaments in an anatomic procedure with the use of an allogeneic or autologous tendon graft (semitendinosus). First the AC joint is relocated carefully and any structures (e.g., a dislocated meniscus or the trapezius muscle) that inhibit anatomic repositioning are carefully evaluated. The graft is passed around the coracoid and through 2 clavicular tunnels and is fixed with tenodesis screws. It is important to place the tunnels in the anatomic insertion area of the trapezoid and conoid ligaments (25 mm and 45 mm medial to the lateral edge of the clavicle).^{37,38} The remaining longer limb (exiting the lateral tunnel) is then used to reconstruct the posterior and superior AC ligaments. Finally the fasciae of the deltoid and trapezius muscles are carefully reattached and interposed over the AC joint.

The use of a free tendon graft placed in an anatomic position attempting to reproduce the trapezoid and conoid ligaments has been shown to perform as the intact CC ligament complex. Costic et al.³⁹ found that the anatomic CC reconstruction more closely approximates the stiffness of the native CC ligaments than does a standard Weaver-Dunn repair. Grutter and Petersen⁴⁰ have also performed a successful variation of reconstructing the AC and CC ligaments.

Limitations

The concepts and careful conclusions presented in this review are largely limited by the lack of high-level studies in the literature. Additionally, the included studies incorporated varying and oftentimes subjective outcome measures when evaluating treatment methods. This variability made it difficult to compare studies and to subsequently draw overall conclusions regarding treatments.

Conclusions

There is a lack of evidence to support treatment options for patients with AC joint dislocations. Although there is a general consensus for nonoperative treatment of Rockwood type I and type II lesions, initial nonsurgical treatment of type III lesions, and operative intervention for Rockwood type IV to VI lesions, further research is needed to determine if differences exist regarding early versus delayed surgical intervention and anatomic versus nonanatomic surgical techniques in the treatment of patients with AC joint dislocations.

References

1. Cave E. *Fractures and other injuries*. Chicago, IL: Year Book Publishers, 1958.
2. Pallis M, Cameron KL, Svoboda SJ, Owens BD. Epidemiology of acromioclavicular joint injury in young athletes. *Am J Sports Med* 2012;40:2072-2077.
3. Drago J, Braun HJ, Bartlinski SE, Harris AH. Acromioclavicular joint injuries in National Collegiate Athletic Association football: data from the 2004-2005 through 2008-2009 National Collegiate Athletic Association injury surveillance system. *Am J Sports Med* 2012;40:2066-2071.
4. Rockwood CA, Green DP. *Fractures in adults*, 2nd ed. Philadelphia, PA: J.B. Lippincott, 1975.
5. Mazzocca AD, Arciero RA, Bicos J. Evaluation and treatment of acromioclavicular joint injuries. *Am J Sports Med* 2007;35:316-329.
6. Larsen E, Bjerg-Nielsen A, Christensen P. Conservative or surgical treatment of acromioclavicular dislocation. A prospective, controlled, randomized study. *J Bone Joint Surg Am* 1986;68:552-555.
7. Bannister GC, Wallace WA, Stableforth PG, Hutson MA. The management of acute acromioclavicular dislocation. A randomised prospective controlled trial. *J Bone Joint Surg Br* 1989;71:848-850.

8. Weinstein DM, McCann PD, McIlveen SJ, Flatow EL, Bigliani LU. Surgical treatment of complete acromioclavicular dislocations. *Am J Sports Med* 1995;23:324-331.
9. Rolf O, Hann von Weyhern A, Ewers A, Boehm TD, Gohlke F. Acromioclavicular dislocation Rockwood III-V: Results of early versus delayed surgical treatment. *Arch Orthop Trauma Surg* 2008;128:1153-1157.
10. Mignani G, Rotini R, Olmi R, Marchiodi L, Veronesi CA. The surgical treatment of Rockwood grade III acromioclavicular dislocations. *Chir Organi Mov* 2002;87:153-161.
11. Dumontier C, Sautet A, Man M, Apoil A. Acromioclavicular dislocations: treatment by coracoacromial ligamentoplasty. *J Shoulder Elbow Surg* 1995;4:130-134.
12. Tauber M, Gordon K, Koller H, Fox M, Resch H. Semitendinosus tendon graft versus a modified Weaver-Dunn procedure for acromioclavicular joint reconstruction in chronic cases: a prospective comparative study. *Am J Sports Med* 2009;37:181-190.
13. Fraschini G, Ciampi P, Scotti C, Ballis R, Peretti GM. Surgical treatment of chronic acromioclavicular dislocation: comparison between two surgical procedures for anatomic reconstruction. *Injury* 2010;41:1103-1106.
14. Bosworth B. Acromioclavicular separation: New method of repair. *Surg Gynecol Obstet* 1941;73:866-871.
15. Mumford E. Acromioclavicular dislocation. *J Bone Joint Surg Am* 1941;23:799-802.
16. Rockwood. Injuries to the acromioclavicular joint: subluxations and dislocations about the shoulder. In: Rockwood CA Jr, Green DP, eds. *Fractures in adults*. Philadelphia: JB Lippincott, 1984;860-910.
17. Bontempo NA, Mazzocca AD. Biomechanics and treatment of acromioclavicular and sternoclavicular joint injuries. *Br J Sports Med* 2010;44:361-369.
18. Tamaoki MJ, Belloti JC, Lenza M, Matsumoto MH, Gomes Dos Santos JB, Faloppa F. Surgical versus conservative interventions for treating acromioclavicular dislocation of the shoulder in adults. *Cochrane Database Syst Rev* 2010: CD007429.
19. Cote MP, Wojcik KE, Gomlinski G, Mazzocca AD. Rehabilitation of acromioclavicular joint separations: operative and nonoperative considerations. *Clin Sports Med* 2010;29: 213-228, vii.
20. Trainer G, Arciero RA, Mazzocca AD. Practical management of grade III acromioclavicular separations. *Clin J Sport Med* 2008;18:162-166.
21. Murena L, Canton G, Vulcano E, Cherubino P. Scapular dyskinesis and SICK scapula syndrome following surgical treatment of type III acute acromioclavicular dislocations. *Knee Surg Sports Traumatol Arthrosc* 2012 Mar 30 [Epub ahead of print].
22. Geaney LE, Miller MD, Ticker JB, et al. Management of the failed AC joint reconstruction: causation and treatment. *Sports Med Arthrosc* 2010;18:167-172.
23. Cadenat FM. The treatment of dislocations and fractures of the outer end of the clavicle. *Internat Clin* 1917:146-149.
24. Weaver JK, Dunn HK. Treatment of acromioclavicular injuries, especially complete acromioclavicular separation. *J Bone Joint Surg Am* 1972;54:1187-1194.
25. Sage FP, Salvatore JE. Injuries of the acromioclavicular joint: a study of results in 96 patients. *South Med J* 1963;56:486-495.
26. Zaricznyj B. Late reconstruction of the ligaments following acromioclavicular separation. *J Bone Joint Surg Am* 1976;58:792-795.
27. Bundens WD Jr, Cook JI. Repair of acromioclavicular separations by deltoid-trapezius imbrication. *Clin Orthop* 1961;20:109-115.
28. Carofino BC, Mazzocca AD. The anatomic coracoclavicular ligament reconstruction: surgical technique and indications. *J Shoulder Elbow Surg* 2010;19:37-46.
29. Mazzocca AD, Santangelo SA, Johnson ST, Rios CG, Dumonski ML, Arciero RA. A biomechanical evaluation of an anatomical coracoclavicular ligament reconstruction. *Am J Sports Med* 2006;34:236-246.
30. Mazzocca AD, Spang JT, Rodriguez RR, et al. Biomechanical and radiographic analysis of partial coracoclavicular ligament injuries. *Am J Sports Med* 2008;36: 1397-1402.
31. Beitzel K, Obopilwe E, Chowaniec DM, et al. Biomechanical comparison of arthroscopic repairs for acromioclavicular joint instability: suture button systems without biological augmentation. *Am J Sports Med* 2011;39: 2218-2225.
32. Beitzel K, Obopilwe E, Chowaniec DM, et al. Biomechanical properties of repairs for dislocated AC joints using suture button systems with integrated tendon augmentation. *Knee Surg Sports Traumatol Arthrosc* 2012;20:1931-1938.
33. Walz L, Salzmann GM, Fabbro T, Eichhorn S, Imhoff AB. The anatomic reconstruction of acromioclavicular joint dislocations using 2 TightRope devices: a biomechanical study. *Am J Sports Med* 2008;36:2398-2406.
34. Salzmann GM, Walz L, Buchmann S, Glabgly P, Venjakob A, Imhoff AB. Arthroscopically assisted 2-bundle anatomical reduction of acute acromioclavicular joint separations. *Am J Sports Med* 2010;38:1179-1187.
35. Tischer T, Salzmann GM, El-Azab H, Vogt S, Imhoff AB. Incidence of associated injuries with acute acromioclavicular joint dislocations types III through V. *Am J Sports Med* 2009;37:136-139.
36. Pauly S, Gerhardt C, Haas NP, Scheibel M. Prevalence of concomitant intraarticular lesions in patients treated operatively for high-grade acromioclavicular joint separations. *Knee Surg Sports Traumatol Arthrosc* 2009;17: 513-517.
37. Rios CG, Arciero RA, Mazzocca AD. Anatomy of the clavicle and coracoid process for reconstruction of the coracoclavicular ligaments. *Am J Sports Med* 2007;35: 811-817.
38. Salzmann GM, Paul J, Sandmann GH, Imhoff AB, Schottle PB. The coracoidal insertion of the coracoclavicular ligaments: an anatomic study. *Am J Sports Med* 2008;36:2392-2397.
39. Costic RS, Labriola JE, Rodosky MW, Debski RE. Biomechanical rationale for development of anatomical reconstructions of coracoclavicular ligaments after complete acromioclavicular joint dislocations. *Am J Sports Med* 2004;32:1929-1936.
40. Grutter PW, Petersen SA. Anatomical acromioclavicular ligament reconstruction: a biomechanical comparison of reconstructive techniques of the acromioclavicular joint. *Am J Sports Med* 2005;33:1723-1728.

41. Rosenorn M, Pedersen EB. A comparison between conservative and operative treatment of acute acromioclavicular dislocation. *Acta Orthop Scand* 1974;45:50-59.
42. Galpin RD, Hawkins RJ, Grainger RW. A comparative analysis of operative versus nonoperative treatment of grade III acromioclavicular separations. *Clin Orthop Relat Res* 1985;150-155.
43. Jacobs B, Wade PA. Acromioclavicular-joint injury. An end-result study. *J Bone Joint Surg Am* 1966;48:475-486.
44. Calvo E, Lopez-Franco M, Arribas IM. Clinical and radiologic outcomes of surgical and conservative treatment of type III acromioclavicular joint injury. *J Shoulder Elbow Surg* 2006;15:300-305.
45. MacDonald PB, Alexander MJ, Frejuk J, Johnson GE. Comprehensive functional analysis of shoulders following complete acromioclavicular separation. *Am J Sports Med* 1988;16:475-480.
46. Taft TN, Wilson FC, Oglesby JW. Dislocation of the acromioclavicular joint. An end-result study. *J Bone Joint Surg Am* 1987;69:1045-1051.
47. Gstettner C, Tauber M, Hitzl W, Resch H. Rockwood type III acromioclavicular dislocation: surgical versus conservative treatment. *J Shoulder Elbow Surg* 2008;17:220-225.
48. Walsh WM, Peterson DA, Shelton G, Neumann RD. Shoulder strength following acromioclavicular injury. *Am J Sports Med* 1985;13:153-158.
49. Bakalim G, Wilppula E. Surgical or conservative treatment of total dislocation of the acromioclavicular joint. *Acta Chir Scand* 1975;141:43-47.
50. Larsen E, Hede A. Treatment of acute acromioclavicular dislocation. Three different methods of treatment prospectively studied. *Acta Orthop Belg* 1987;53:480-484.
51. Press J, Zuckerman JD, Gallagher M, Cuomo F. Treatment of grade III acromioclavicular separations. Operative versus nonoperative management. *Bull Hosp Jt Dis* 1997;56:77-83.
52. Cardone D, Brown JN, Roberts SN, Saies AD, Hayes MG. Grade III acromioclavicular joint injury in Australian Rules Football. *J Sci Med Sport* 2002;5:143-148.